

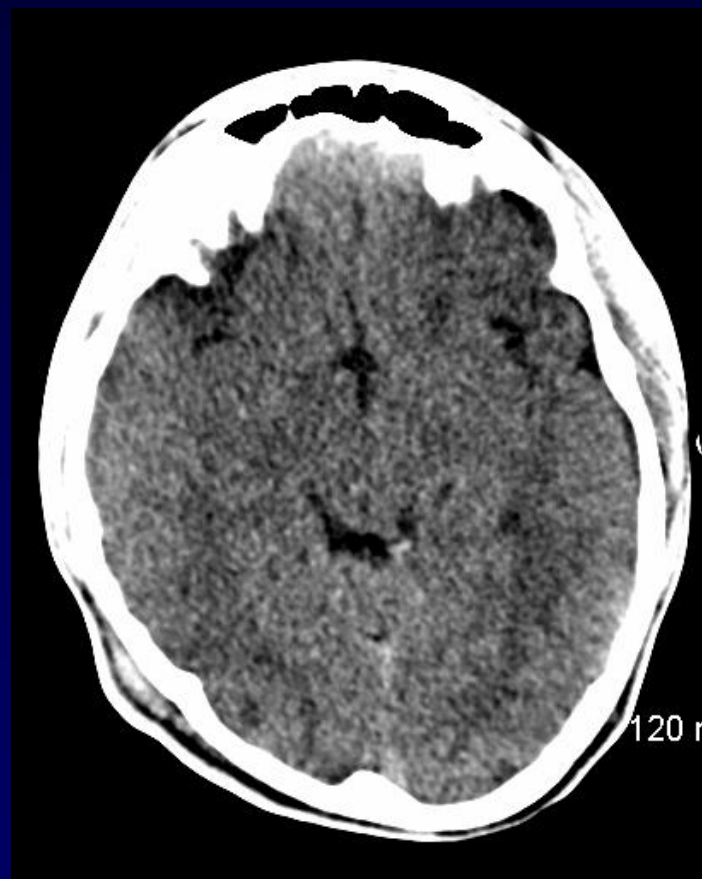
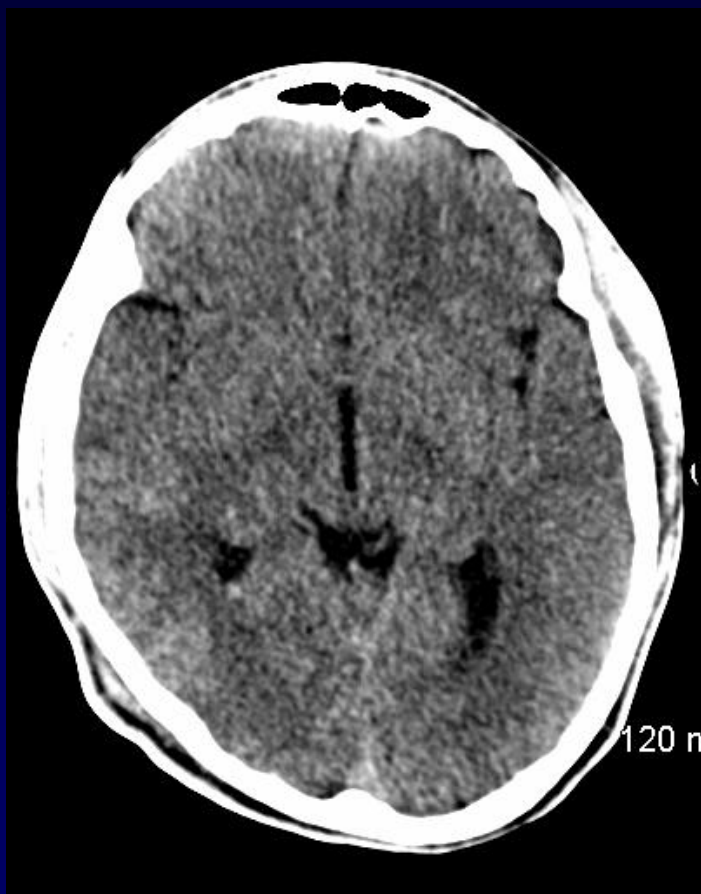

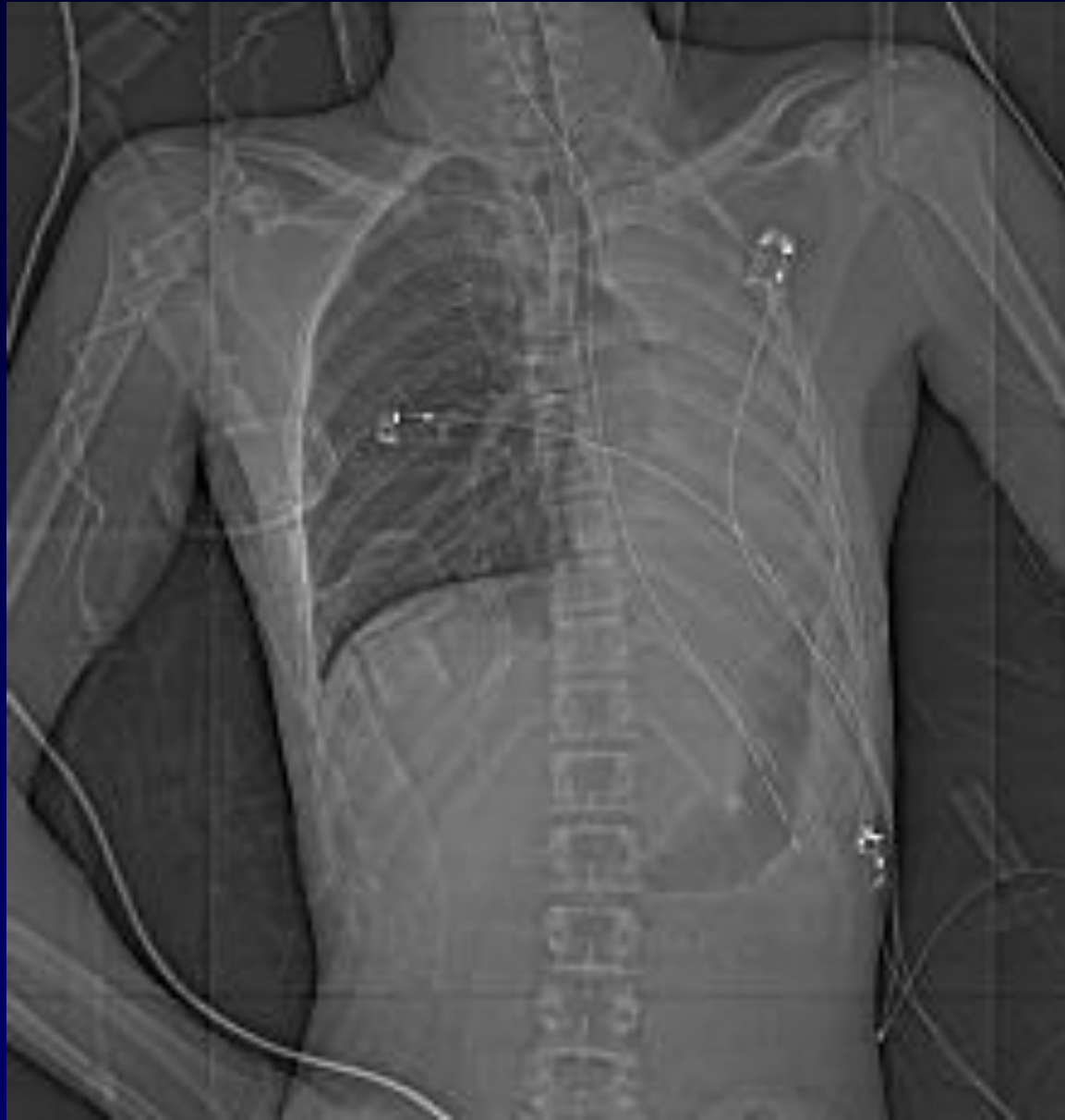J GIRON – P FAJADET

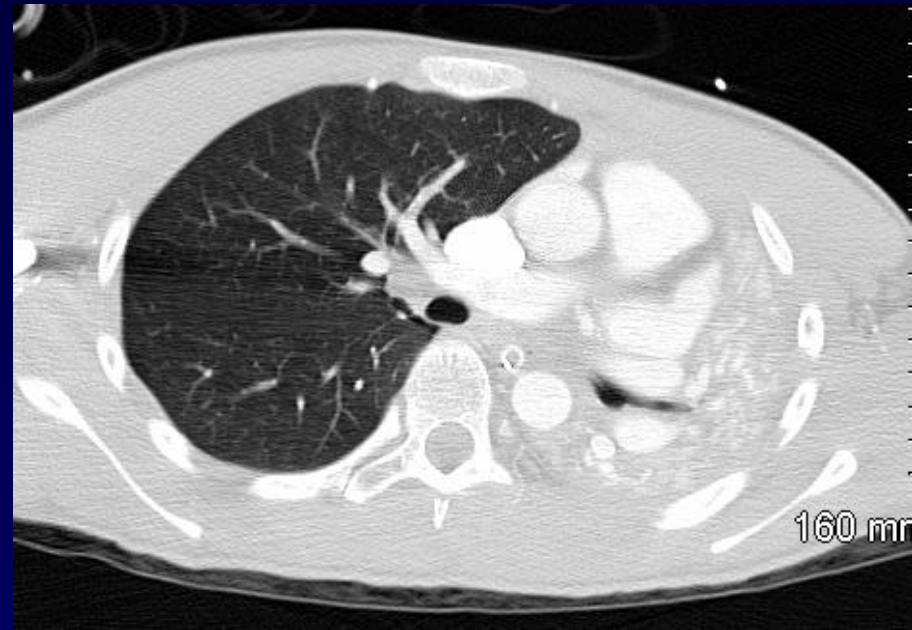
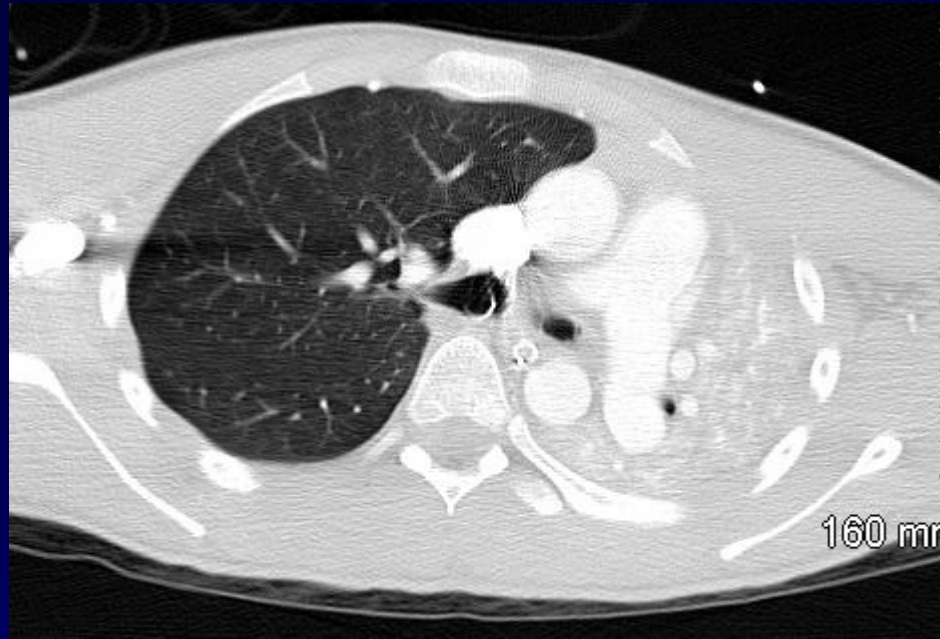Homme de 15 ans

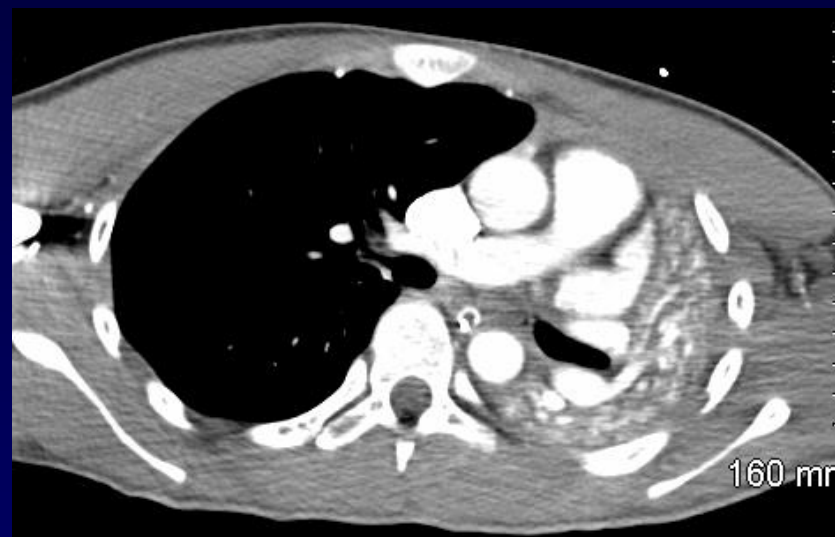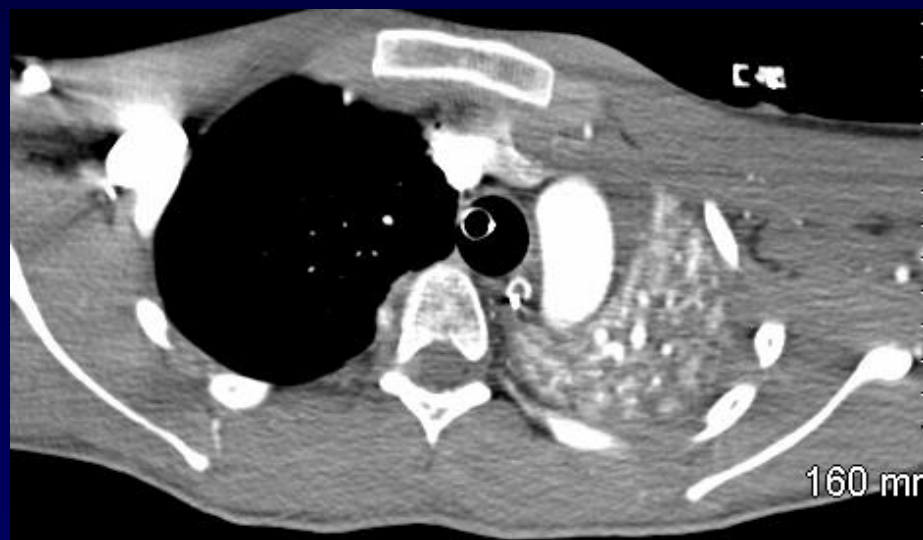
TRAUMA AVP

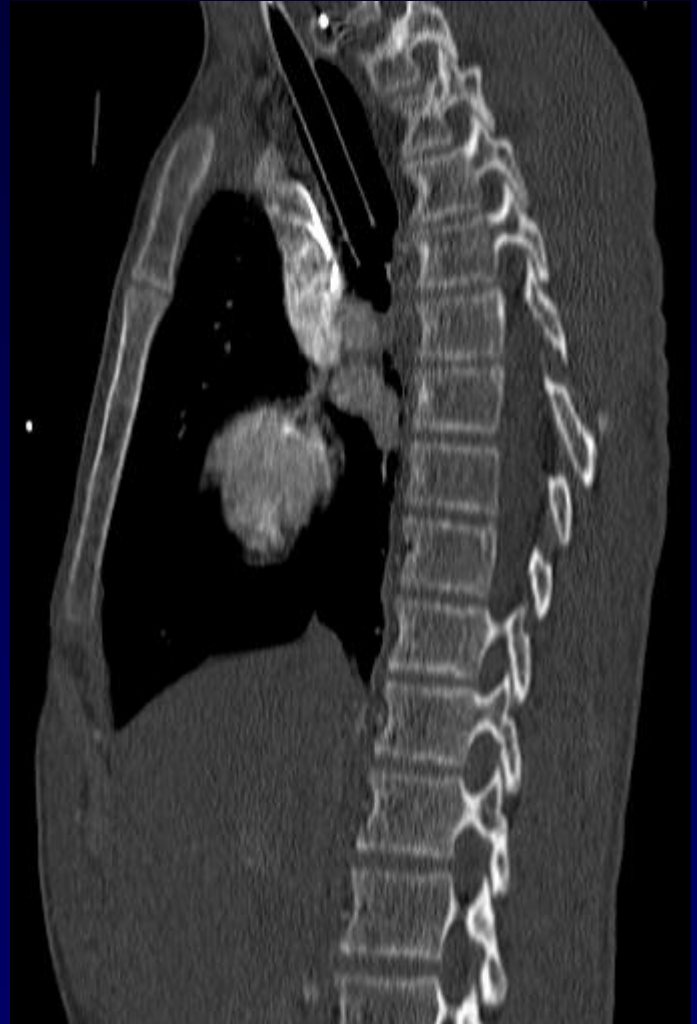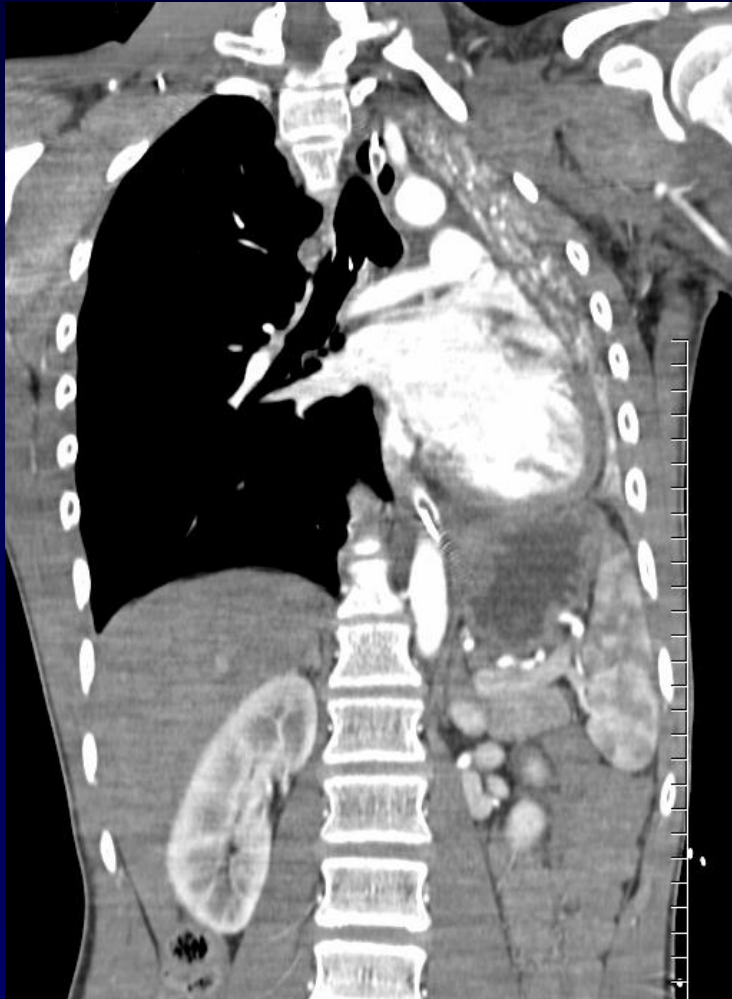
TDM CORPS ENTIER APRES INTUBATION













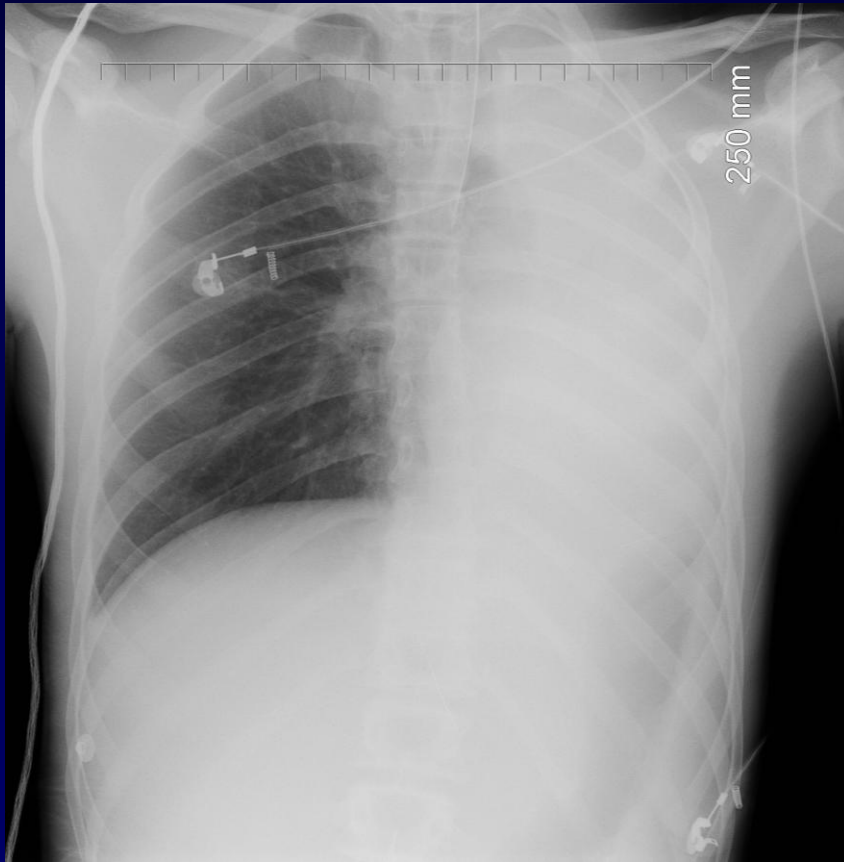
Diagnostic ?



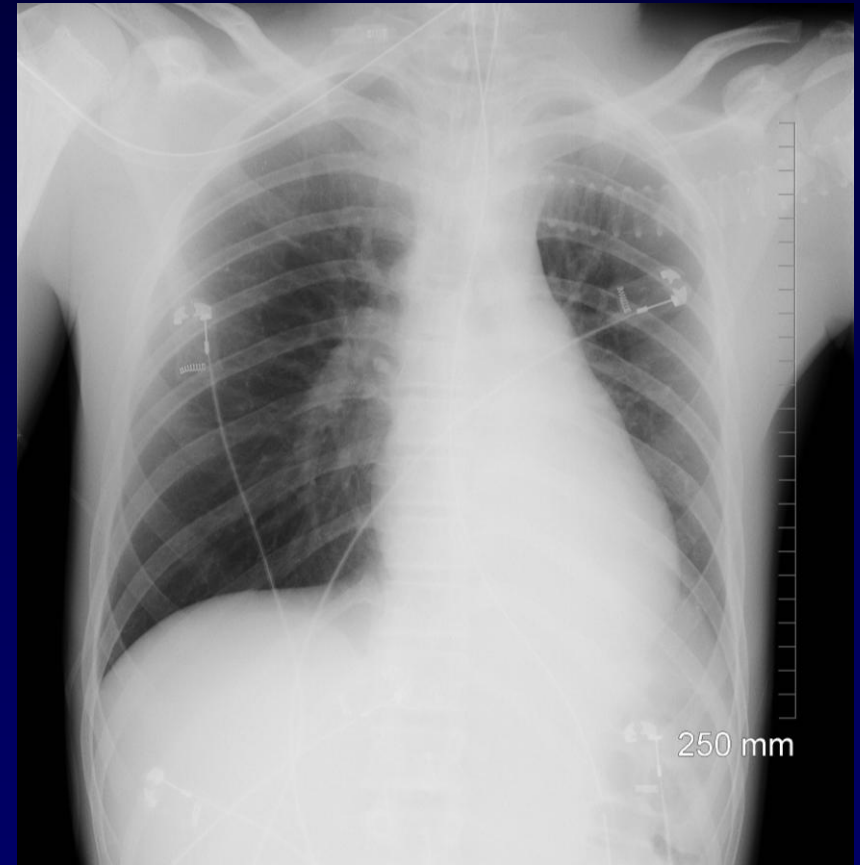
INTUBATION SELECTIVE ATELECTASIE POUUMON GAUCHE



Evolution-Discussion-Point fort



AVANT



APRES